

A follow-up study of early interceptive treatment of primary anterior crossbites

YuanShu Ge, Jin Liu, Xin Guo and JianLi Han

Department of Orthodontics, ShenZhen Children's Hospital, China

Correspondence to: Dr YuanShu Ge, Department of Orthodontics, ShenZhen Children's Hospital, 7019 YiTian Road, FuTian District, ShenZhen City 518026, Guangdong, China. E-mail: frankge18@hotmail.com

SUMMARY The purpose of this study was to investigate the outcome of early interceptive treatment of primary anterior crossbites with posterior occlusal acrylic resin blocks in combination with a 2 × 4 appliance, and to examine the differences in craniofacial morphology between the stable and relapse groups. Lateral cephalograms of 46 subjects (17 males and 29 females; average mean age 4 years 2 months ± 5 months) with a primary anterior crossbite were obtained before (T0) and immediately after (T1) treatment and at a 6 year follow-up (T2). The patients were assigned to either a stable ($n = 35$; 13 males and 22 females) or a relapse ($n = 11$; 4 males and 7 females) group according to the amount of overjet when the permanent incisors had erupted. The differences in craniofacial morphology between the groups were compared using a two-tailed *t*-test.

The results revealed that the relapse subjects had a more forward position of the mandible relative to the cranial base and maxilla, a longer mandible and an increased gonial angle at T0. At T1, both groups had a positive overjet, but the treatment changes were different. Between T1 and T2, the maxillary length (A'–Ptm') increased less in the relapse group, the angle between the posterior border of the mandibular ramus and SN plane (Ram–SN) decreased and gonial angle increased and *vice versa* in the stable group.

When posterior bite raising and 2 × 4 appliance therapy are used to correct primary anterior crossbites, all patients showed an immediate positive treatment response, whereas approximately one-quarter of subjects relapsed into a reverse overjet when the permanent incisors had erupted, mainly because of a more severe Class III craniofacial morphology at T1 and unfavourable growth during T1–T2.

Introduction

In the Chinese population, the prevalence of a Class III malocclusion is comparatively high, ranging from 8.3 to 13 per cent (Yao, 1984; Hua and Shi, 2000; Huang *et al.*, 2005). An anterior crossbite may be regarded as an aesthetic problem. Parents, upon noticing such abnormalities in the primary dentition of their children, often enquire as to whether or not treatment is required (Saadia and Torres, 2000).

Without treatment, the skeletal malocclusion may be aggravated as the patient grows (Graber, 1977; Takeuchi *et al.*, 1979). However, some primary anterior crossbites can spontaneously correct during either the primary or the transitional dentition (Nagahara *et al.*, 1997, 2001; Wang *et al.*, 1999). Timing of orthodontic treatment, early or late, is a dilemma for orthodontists. The deciduous indicator (DI) developed by Nagahara *et al.* (2001) is a useful method to evaluate the necessity of early treatment for primary anterior crossbites.

Various appliances have been devised for early interceptive treatment of a crossbite, such as reverse headgears, chin-cups, functional appliances, removable plates with springs, and simple fixed appliances (Thilander,

1965; Graber, 1977; Deguchi *et al.*, 1999; Gu *et al.*, 2000; Onodera *et al.*, 2006). Patient compliance is essential for successful treatment, especially in the young child. Several authors have reported that posterior bite raising is a patient-friendly treatment method in the primary dentition as minimal cooperation is required (Miyajima *et al.*, 1995; al-Sehaibany and White, 1996; Tzatzakis and Gidarakou, 2008). However, there is no information in the literature concerning the long-term effects of posterior bite raising in patients with a primary anterior crossbite.

The aim of this study was to evaluate both active treatment and post-treatment outcomes of posterior bite raising in combination with a 2 × 4 appliance in children with a primary anterior crossbite, and to examine the differences in craniofacial morphology between the stable and relapse group.

Subjects and methods

Forty-six consecutive Chinese patients (17 males and 29 females; average mean age 4 years 2 months ± 5 months) from a total of 69 subjects with primary anterior crossbites were included in this study. Inclusion was based on the

following criteria: 1. Hellman's developmental stage IIA of the primary dentition, at which time the second primary molars had erupted while the permanent incisors had not begun to erupt (Hellman, 1932); 2. a crossbite involving all eight primary incisors and both mandibular primary canines; 3. no tooth loss, no history of caries, or previous crown restoration; 4. DI greater than 0 (Nagahara *et al.*, 2001). $DI = -0.58$ (anterior cranial length) $+1.31$ (posterior face height) -0.76 (porion location) -2.02 (Wits appraisal) -70.18 . The lower the DI value (negative), the higher the probability that a crossbite will self-correct during the transitional dentition. On the other hand, a high (positive) value strongly suggests that the subject requires treatment in the primary dentition.

Posterior occlusal acrylic resin blocks were bonded to the mandibular primary molars (T0; Figure 1a). This removed incisal interferences while the anterior crossbite was corrected with a 2×4 appliance (Figure 1b), comprising buccal tubes on the second primary maxillary molars, brackets on the maxillary incisors, and a wire with advancing loops (Major and Glover, 1992). At the end of treatment (T1), after a mean treatment time of 6 months, all subjects attained a positive overjet. At the 6 year follow-up (T2), the permanent maxillary and mandibular incisors had erupted. According to the amount of overjet, the patients were

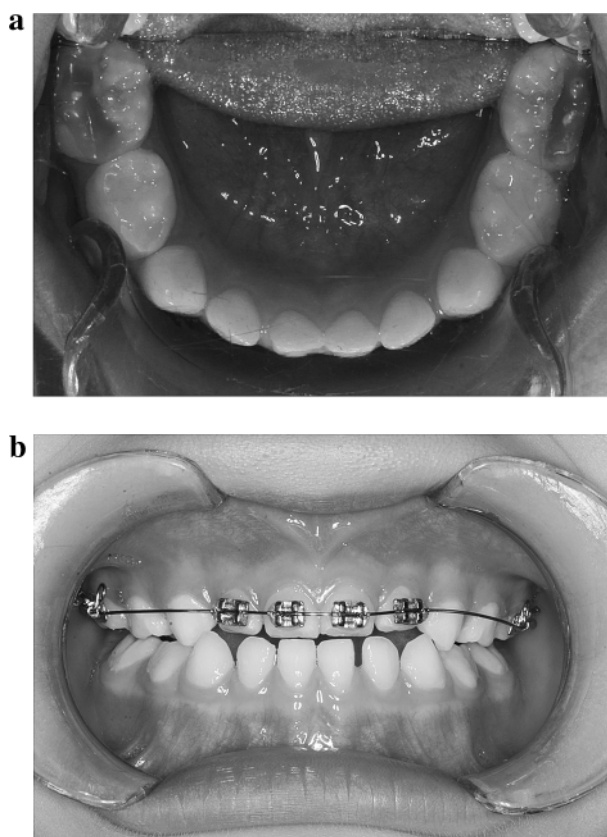


Figure 1 (a) Posterior occlusal acrylic resin blocks and (b) 2×4 appliance.

divided into two groups. Those with a positive overjet were defined as stable ($n = 35$; 13 males and 22 females) and those with a negative overjet or an edge-to-edge incisor relationship as relapse ($n = 11$; 4 males and 7 females). The mean ages at the various time periods in both groups and the duration of treatment and observation are shown in Table 1.

Lateral cephalograms were obtained at T0, T1, and T2. Therefore, T0–T1 represented the treatment changes, T1–T2 the changes during the follow-up period, and T0–T2 the total changes during treatment and follow-up. Lateral cephalograms were analysed using the method of Iizuka (1953) and Sakamoto *et al.* (1963). The 11 angular measurements are shown in Figure 2a and the 17 linear measurements in Figure 2b. The following landmarks were used: is (the edge of the upper central incisors), ii (the edge of the lower central incisor), ms (the midpoint on the occlusal surface of the upper second primary molar), and mi (the midpoint on the occlusal surface of the lower second primary molar); S', ptm', A', is', and ms' are perpendicular to the nasal line (NL) from S, ptm, A, is, and ms; Pog', ii', and mi' are perpendicular to the mandibular plane (MP) from Pog, ii, and mi.

Measurement error

The lateral cephalograms were traced by one author (YSG) and checked by another (JL). To evaluate tracing and measurement errors, 60 lateral cephalograms of 20 patients were randomly selected and remeasured by the same investigator 1 month later. The estimate of random errors was made using Dahlberg's formula (Houston, 1983). No systematic errors were found. The mean errors for angular and linear measurements were from 0.4 to 1.4 degrees and from 0.1 to 1.2 mm, respectively.

Statistical analysis

For cephalometric analysis, comparison of treatment changes between the stable and relapse groups was undertaken using a two-tailed *t*-test. All statistical analyses were performed with the Statistical Package for Social Sciences version 12.0 (SPSS Inc; Chicago, Illinois, USA).

Table 1 Ages at the start of treatment (T0), end of treatment (T1), and at the 6 year follow-up (T2). SD, standard deviation.

	Relapse group ($n = 11$)	Stable group ($n = 35$)
	Mean (SD; years/months)	Mean (SD; years/months)
T0	4.1 (0.6)	4.3 (0.5)
T1	4.8 (0.6)	4.9 (0.6)
T2	10.4 (1.3)	10.7 (1.1)
T0–T1	0.6 (0.1)	0.6 (0.2)
T0–T2	6.3 (1.1)	6.4 (1.2)

Duration of treatment (T0–T1)/observation period (T0–T2).

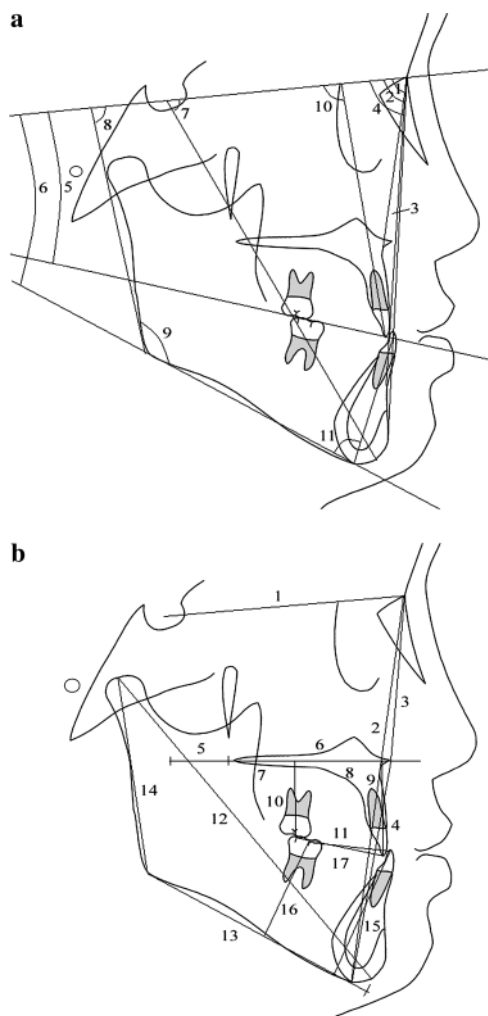


Figure 2 (a) Angular measurements: 1, SNA; 2, SNB; 3, ANB; 4, SNP; 5, SN-OP; 6, SN-MP; 7, SN-Gn; 8, ram(SN); 9, gonial angle; 10, UA-SN; 11, LA-MP and (b) linear measurements: 1, N-S; 2, N-Me; 3, N-Ans; 4, Ans-Me; 5, S'-ptm'; 6, A'-ptm'; 7, Ptm'-ms'; 8, A'-ms'; 9, is-is'; 10, ms-ms'; 11, is-ms; 12, Gn-Cd; 13, Pog'-Go; 14, Cd-Go; 15, ii-ii'; 16, mi-mi'; 17, ii-mi.

Results

Dentofacial morphology

At T0, the antero-posterior position of the mandible relative to the cranial base and maxilla, as indicated by s-n-pog (SNP), s-n-gn (SN-Gn), and n-ss-sm (ANB) angles, was more forward in the relapse group (Table 2). Mandibular length (Cd-Gn), gonial angle, and the angle between the tooth axis of the maxillary incisor and anterior cranial base (UA-SN) were significantly greater in the relapse than in the stable group. Mandibular body length (Pog'-Go) and ramus height (Cd-Go) showed similar mean values.

No statistically significant differences in dentofacial morphology were found between the groups at T1 (Table 2). The only exceptions were a smaller value for ANB and a larger value for Pog'-Go in the relapse group.

At T2, among the variables representing the antero-posterior position of the mandible relative to the cranial base and maxilla, s-n-sm angle (SNB), SNP, and SN-Gn were significantly greater and ANB was significantly smaller in the relapse group (Table 2). The mean gonial angle was approximately 10.7 degrees greater, and the angle between the posterior border of the mandibular ramus and SN plane (Ram-SN) was 9.8 degrees less in the relapse than in the stable group.

Maxillary length (A'-Ptm') was significantly smaller in the relapse group. In the mandible, Pog'-Go and Gn-Cd were greater in the relapse group, but the difference was not significant. Cd-Go showed similar mean values. The angle between the tooth axis of the mandibular incisor and mandibular plane (LA-MP) showed significant mandibular incisor retroclination in the relapse group.

Treatment changes

ANB increased in both groups during T0-T1, but this was only significant in the relapse group (Table 3). For the dental variables, there was a statistically significant protrusion of the maxillary incisors and retrusion of the mandibular incisors but only in the stable group. UA-SN and upper arch length (is-ms) increased and LA-MP and lower arch length (ii-mi) decreased in the stable group.

Anterior cranial base length (N-S), total face height (N-Me), anterior upper face height (Ans-Me), Pog'-Go, Gn-Cd, and Cd-Go increased significantly in both groups during T1-T2, but there was no difference between the groups (Table 3). SNB and SNP increased more in the relapse group. A'-Ptm' increased in the stable group, but showed no significant change in the relapse group. During T1-T2, the changes of Ram-SN and gonial angle were statistically different between the groups. In the relapse group, Ram-SN increased and gonial angle decreased, whereas Ram-SN decreased and gonial angle increased in the stable group.

UA-SN and LA-MP increased in both groups, but the increase of LA-MP in the relapse group was not significant. Following eruption of the first permanent molars and permanent incisors, maxillary (ms-ms') and mandibular (mi-mi') molar height, and maxillary (is-is') and mandibular (ii-ii') incisor height increased in both group.

Total changes

During T0-T2, the maxilla grew less in the relapse group than in the stable group (Table 3). The mandible grew more in the relapse group, but the differences were not statistically significant. The changes of Ram-SN and gonial angle were especially marked. Ram-SN increased in the stable group but decreased in the relapse group. Gonial angle decreased in the stable group but increased in the relapse group. The maxillary and mandibular incisors protruded significantly in the stable group. In the relapse group, the increase of LA-MP was not significant.

Table 2 Dentofacial morphology of the primary anterior crossbite subjects at the start (T0) and end (T1) of treatment and at the 6 year follow-up (T2).

	T0				T1				T2			
	Stable (S), mean \pm SD	Relapse (R), mean \pm SD	S-R		Stable, mean \pm SD	Relapse, mean \pm SD		S-R	Stable, mean \pm SD	Relapse, mean \pm SD		S-R
			<i>d</i>	<i>P</i>								
Angular measurements												
SNA	80.9 \pm 2.3	78.2 \pm 2.46	2.7	0.107	81.1 \pm 1.7	78.4 \pm 2.39	2.7	0.096	82.1 \pm 1.7	79.1 \pm 1.70	3.0	0.189
SNB	79.4 \pm 2.0	81.3 \pm 1.80	-1.9	0.095	78.7 \pm 1.9	79.7 \pm 2.59	-1.0	0.932	80.9 \pm 1.3	83.6 \pm 1.71	-2.7**	0.003
ANB	2.5 \pm 1.9	-3.1 \pm 1.38	4.6**	0.001	3.4 \pm 1.4	-1.4 \pm 0.65	3.7*	0.013	1.2 \pm 1.5	-4.5 \pm 1.55	5.7***	0.000
SNP	77.3 \pm 2.3	80.6 \pm 1.32	-3.3*	0.044	76.9 \pm 2.2	78.2 \pm 3.05	-1.3*	0.748	79.8 \pm 2.0	84.0 \pm 1.65	-4.2**	0.003
SN-OP	19.6 \pm 2.7	18.4 \pm 1.62	1.2	0.133	20.1 \pm 3.1	18.5 \pm 1.70	1.6	0.739	18.8 \pm 2.1	18.7 \pm 2.94	0.1	0.774
SN-MP	32.1 \pm 4.5	32.9 \pm 4.20	-0.8	0.683	31.2 \pm 4.2	32.2 \pm 2.59	-1.0	0.862	31.5 \pm 4.6	33.4 \pm 3.1	-1.9	0.788
SN-Gn	66.5 \pm 3.1	64.60 \pm 1.28	1.9*	0.038	67.7 \pm 3.0	64.9 \pm 1.72	1.8	0.522	68.1 \pm 3.4	64.8 \pm 1.40	3.3*	0.030
Ram-SN	87.2 \pm 3.5	84.3 \pm 1.65	2.9	0.104	87.3 \pm 6.7	86.8 \pm 2.25	0.5	0.421	92.3 \pm 2.3	82.5 \pm 6.19	9.8**	0.003
Go angle	127.4 \pm 4.6	132.3 \pm 6.62	-4.9*	0.037	126.8 \pm 3.1	130.7 \pm 1.71	-3.9*	0.173	124.0 \pm 5.0	134.7 \pm 8.81	-10.7**	0.008
UA-SN	83.8 \pm 6.4	97.0 \pm 3.82	-13.2***	0.000	96.5 \pm 3.7	101.3 \pm 5.6	-4.8	0.216	113.0 \pm 1.7	113.8 \pm 4.40	-0.8	0.570
LA-MP	85.5 \pm 6.4	79.4 \pm 3.66	6.1	0.084	82.5 \pm 6.1	79.3 \pm 7.66	3.2	0.245	97.5 \pm 5.5	82.7 \pm 3.57	14.8**	0.001
Linear measurements												
N-S	56.3 \pm 2.9	56.0 \pm 3.13	0.3	0.444	56.4 \pm 2.8	56.2 \pm 1.78	0.2	0.529	60.7 \pm 4.1	58.7 \pm 4.16	2.0	0.446
N-Me	89.8 \pm 4.4	89.7 \pm 3.16	0.1	0.976	90.1 \pm 3.3	89.2 \pm 4.73	0.9	0.123	104.4 \pm 5.8	100.8 \pm 6.09	3.6	0.384
N-Ans	40.2 \pm 2.2	38.7 \pm 3.39	1.5	0.570	39.8 \pm 1.6	40.5 \pm 3.73	-0.7	0.212	46.3 \pm 2.7	44.7 \pm 3.95	1.6	0.247
Ans-Me	50.7 \pm 3.1	50.6 \pm 2.34	0.1	0.964	51.3 \pm 2.2	49.8 \pm 1.02	-1.5	0.679	58.8 \pm 4.0	56.3 \pm 3.26	2.5	0.859
S' ptm'	17.2 \pm 2.3	18.9 \pm 3.23	-1.7	0.218	17.6 \pm 2.0	19.00 \pm 2.17	-1.4	0.065	18.3 \pm 3.4	19.8 \pm 1.85	-1.5	0.478
A' ptm'	36.9 \pm 2.2	35.9 \pm 2.14	1.1	0.395	37.4 \pm 1.7	36.3 \pm 1.55	1.1	0.919	41.1 \pm 1.7	37.0 \pm 3.96	4.1**	0.001
Ptm'-ms'	16.4 \pm 2.0	17.8 \pm 2.89	-1.4	0.363	16.5 \pm 1.4	16.1 \pm 1.74	-0.4	0.797	15.7 \pm 3.3	12.5 \pm 2.68	3.2	0.144
A'-ms'	21.4 \pm 1.9	18.5 \pm 2.59	2.9	0.083	20.8 \pm 1.1	20.3 \pm 1.29	0.5	0.900	24.2 \pm 4.3	24.1 \pm 3.39	0.1	0.734
is-is'	22.0 \pm 1.4	22.5 \pm 1.01	-0.5	0.570	22.6 \pm 1.2	21.6 \pm 1.32	1.0	0.112	24.6 \pm 2.1	23.7 \pm 1.63	0.9	0.443
ms-ms'	16.0 \pm 2.1	16.8 \pm 3.04	-0.8	0.186	15.9 \pm 1.2	15.2 \pm 1.48	0.3	0.736	18.1 \pm 2.7	17.9 \pm 2.64	0.2	0.881
is-ms	20.5 \pm 1.8	22.1 \pm 1.44	-1.6	0.125	23.0 \pm 1.4	23.4 \pm 3.14	-0.4	0.230	32.3 \pm 4.8	33.4 \pm 3.39	2.4	0.424
Gn-Cd	84.8 \pm 3.8	87.7 \pm 2.36	-2.9*	0.028	84.9 \pm 3.2	89.8 \pm 5.75	-3.9*	0.021	99.7 \pm 5.8	103.4 \pm 6.01	-3.7	0.549
Pog'-Go	54.3 \pm 2.9	56.3 \pm 1.86	-2.0	0.055	54.4 \pm 2.3	57.8 \pm 4.26	-3.7	0.051	64.1 \pm 4.6	67.1 \pm 5.40	-3.0	0.748
Cd-Go	41.2 \pm 2.4	42.8 \pm 2.84	-1.6	0.888	41.6 \pm 2.5	43.9 \pm 2.58	-2.3	0.434	50.9 \pm 3.6	49.3 \pm 4.52	1.6	0.160
ii-ii'	32.2 \pm 1.8	30.9 \pm 0.61	1.3	0.935	32.0 \pm 1.1	30.2 \pm 1.19	1.8	0.934	36.1 \pm 2.5	35.2 \pm 1.47	0.9	0.638
mi-mi'	24.3 \pm 1.0	22.6 \pm 1.33	1.7	0.093	25.0 \pm 1.2	24.5 \pm 1.30	0.5	0.644	27.7 \pm 1.5	24.3 \pm 3.13	3.5	0.077
ii-mi	19.7 \pm 1.8	18.8 \pm 1.24	0.9	0.510	18.9 \pm 1.6	18.4 \pm 1.17	0.5	0.563	27.5 \pm 3.9	26.3 \pm 3.53	1.2	0.568

* $P < 0.05$; ** $P < 0.01$; *** $P < 0.001$.

Table 3 Treatment changes (T0–T1), post-treatment changes (T1–T2), and total changes (T0–T3) of the primary anterior crossbite subjects.

T0-T1			T1-T2			T0-T2						
Stable (S), mean ± SD	Rrelapse (R), mean ± SD	S-R	P	Stable, mean ± SD	Relapse, mean ± SD	S-R	P	Stable, mean ± SD	Relapse, mean ± SD	S-R	P	
												d
Angular measurements												
SNA	0.2 ± 1.8	0.2 ± 3.4	0.0	0.364	1.0 ± 1.9	0.7 ± 1.5	0.3	0.944	1.2 ± 2.0	0.9 ± 3.5	0.3	0.862
SNB	-0.7 ± 1.7	-1.6 ± 2.6	0.9	0.761	2.2 ± 1.7	3.9 ± 2.6*	-1.7	0.182	1.5 ± 1.4	2.4 ± 2.9	-0.9	0.461
ANB	0.9 ± 1.3	1.7 ± 1.1*	-0.8*	0.042	-2.2 ± 1.3	-3.1 ± 3.1	0.9	0.201	-1.2 ± 2.3	-1.4 ± 3.6	0.1	0.482
SNP	-0.4 ± 1.6	-2.4 ± 2.2	2.0	0.598	2.9 ± 1.7	5.8 ± 2.3*	-2.9	0.172	2.5 ± 1.6	3.4 ± 2.7*	-0.9	0.364
SN-OP	0.5 ± 2.4	0.1 ± 2.1	0.4	0.742	-1.3 ± 2.2	0.2 ± 1.9	-1.5	0.833	-0.8 ± 3.8	0.3 ± 3.9	-1.1	0.874
SN-MP	-0.9 ± 2.4	-0.7 ± 4.5	-0.2	0.162	0.3 ± 2.4	1.2 ± 4.3	-0.9	0.254	-0.6 ± 1.4	0.5 ± 0.8	-1.1	0.833
SN-Gn	1.2 ± 1.9	0.3 ± 2.8	0.9	0.613	0.4 ± 1.6	-0.1 ± 1.2	0.5	0.912	1.6 ± 1.6	0.2 ± 2.0	1.4	0.518
Ram (SN)	0.1 ± 5.6	2.5 ± 3.0	-2.4	0.210	5.0 ± 2.7*	-4.3 ± 5.8*	9.3**	0.003	5.1 ± 3.5*	-1.8 ± 5.3	6.9**	0.003
Go angle	-0.6 ± 2.9	-1.6 ± 6.2	1.0	0.051	-2.8 ± 3.3	4.0 ± 9.1*	-6.8**	0.005	-3.4 ± 3.9*	2.4 ± 5.8	-5.8**	0.006
UA-SN	12.7 ± 4.7***	4.3 ± 9.2	8.4***	0.000	16.5 ± 5.3**	12.5 ± 9.0*	4.0	0.463	29.2 ± 7.2***	16.8 ± 4.8**	12.4	0.088
LA-MP	-3.0 ± 3.3**	-0.1 ± 8.7	-2.9	0.154	15.0 ± 5.5**	3.4 ± 13.4	11.6	0.111	12.0 ± 5.7*	3.3 ± 6.9	9.7	0.161
Linear measurements												
N-S	0.1 ± 1.1	0.2 ± 1.7	-0.1	0.876	4.3 ± 2.4*	2.5 ± 3.1*	1.8	0.123	4.4 ± 2.7*	2.7 ± 2.0*	1.7	0.199
N-Me	0.3 ± 2.2	-0.5 ± 5.7	0.8	0.755	14.3 ± 5.4**	11.7 ± 6.2**	2.6	0.816	14.6 ± 4.9**	11.2 ± 3.8**	3.4	0.346
N-Ans	-0.4 ± 1.8	1.8 ± 5.2	-2.2	0.081	6.5 ± 2.5	4.2 ± 4.5	2.3	0.680	6.1 ± 2.2	6.0 ± 2.3	0.1	0.798
Ans-Me	0.6 ± 1.7	-0.8 ± 2.6	1.4	0.752	7.5 ± 3.7*	6.5 ± 3.3*	1.0	0.965	8.1 ± 3.3*	5.7 ± 1.7*	2.4	0.230
S'-ptm'	0.4 ± 1.6	0.1 ± 4.0	0.3	0.689	0.7 ± 1.8	0.8 ± 2.8	-0.1	0.667	1.1 ± 2.0	0.9 ± 1.8	2.0	0.750
A'-ptm'	0.5 ± 1.1	0.4 ± 2.4	0.1	0.886	3.7 ± 1.7*	0.7 ± 2.8	3.0	0.114	4.2 ± 1.1**	1.1 ± 3.2	3.1	0.111
Ptm'-ms'	0.1 ± 1.6	-1.7 ± 3.0	1.8	0.121	-0.8 ± 3.6	-3.6 ± 2.9*	2.8	0.321	-0.7 ± 4.7	-5.3 ± 2.4*	4.6	0.161
A'-ms'	-0.6 ± 1.2	1.8 ± 2.2	-2.4	0.120	3.4 ± 4.9*	3.8 ± 3.1*	-0.4	0.788	2.8 ± 5.7*	5.6 ± 3.4*	-2.8	0.798
is-is'	0.6 ± 1.9	-0.9 ± 2.2	1.5	0.911	2.0 ± 2.6*	2.1 ± 2.6*	-0.1	0.981	2.6 ± 1.4*	1.2 ± 0.8*	1.4	0.117
ms-ms'	-0.1 ± 2.1	-1.6 ± 3.5	1.5	0.306	2.2 ± 2.7	2.7 ± 3.1	-0.5	0.940	2.1 ± 3.0	1.1 ± 1.1	1.0	0.166
is-ms	2.5 ± 2.4***	1.3 ± 3.2	1.2	0.505	9.3 ± 5.2**	10.0 ± 5.9**	-0.7	0.232	11.8 ± 6.4***	11.3 ± 4.1**	0.5	0.522
Gn-Cd	0.1 ± 0.9	2.1 ± 5.4	-2.0	0.173	14.8 ± 4.1**	13.6 ± 7.1**	-1.2	0.888	14.9 ± 4.6**	15.7 ± 4.3**	-0.8	0.790
Pog'-Go	0.1 ± 1.9	1.5 ± 3.8	-1.4	0.052	9.7 ± 3.0**	9.3 ± 7.1**	0.4	0.987	9.8 ± 3.2**	10.8 ± 4.9**	-1.0	0.988
Cd-Go	0.4 ± 1.5	1.1 ± 3.7	-0.7	0.418	9.3 ± 4.2**	5.4 ± 4.1*	3.9	0.211	9.7 ± 3.3**	6.5 ± 2.8**	3.2	0.198
ii-ii'	-0.2 ± 0.8	-0.7 ± 1.7	0.5	0.143	4.1 ± 2.5*	5.0 ± 1.9*	-0.9	0.773	3.9 ± 2.5*	4.3 ± 1.5*	-0.4	0.370
mi-mi'	0.7 ± 1.1	1.9 ± 1.6	-1.2	0.237	2.7 ± 1.0	-0.2 ± 3.3	2.9	0.101	3.4 ± 1.5	1.7 ± 2.6	1.7	0.172
ii-mi	-0.8 ± 0.9**	-0.3 ± 1.0	-0.5	0.389	8.7 ± 5.4*	7.9 ± 4.5*	0.8	0.535	7.8 ± 5.8*	7.5 ± 4.1*	0.3	0.669

* $P < 0.05$; ** $P < 0.01$; *** $P < 0.001$.

Discussion

Some primary anterior crossbites can spontaneously correct during either the primary or the transitional dentition, but others persist or even deteriorate (Nagahara *et al.*, 1997, 2001; Wang *et al.*, 1999). Therefore, evaluating the possibility of self-correction of an anterior crossbite at an early stage may enable clinicians to distinguish between subjects who require early treatment from those who do not. The DI is a solution to the dilemma of whether or not to attempt early interception of Class III malocclusions (Nagahara *et al.*, 2001). In that study, DI successfully identified 95.46 per cent of patients in the sample from which it was derived. Extrapolating this information to the 46 patients in the present study, theoretically, the anterior crossbites of 44 subjects would persist during the transitional dentition without treatment all patients in the present study achieved a positive overjet during, on average, 6 months of active treatment. Only 11 of the 46 patients had a negative overjet or edge-to-edge incisor relationship at T2. At T2, as most of the treated subjects were at the beginning of the pubertal growth spurt, it was not possible not predict the degree of treatment stability (Björk, 1963, 1972; Thilander *et al.*, 2005). However, treatment was considered effective because the number of subjects whose anterior crossbite would be assumed to persist in the transitional dentition reduced from 44 to 11. Treatment of primary anterior crossbites in this study fulfilled the expected objectives of interceptive treatment by preventing the existing problem from deteriorating, providing a more favourable environment for normal growth and improving facial aesthetics for more normal psychosocial development (Campbell, 1983).

An increasing number of clinicians believe in the advantages of early intervention. The alternative treatments for this type of malocclusion, which have been shown to be effective include the use of facemasks, chin-cups, and functional appliances (Thilander, 1965; Deguchi *et al.*, 1999; Onodera *et al.*, 2006). In the current study, a simple patient-friendly therapy was used (Miyajima *et al.*, 1995; Tzatzakis and Gidarakou, 2008). Compared with a control group, Chang *et al.* (1992) observed that the Class III primary dentition group showed significant maxillary incisor retrusion. Retroclined upper incisors may cause dental interference during the path of closure of the mandible, leading to mandibular displacement in a forward and upward direction to achieve function. The 2 × 4 appliance is effective in proclining retroclined upper incisors while removing incisal interferences with posterior occlusal acrylic resin blocks. After active treatment, the upper incisors were proclined on average by 16.5 degrees in the stable group and 12.5 degrees in the relapse group.

Early signs of Class III skeletal disharmony in anterior crossbite subjects are present during the primary dentition (Tollaro *et al.*, 1994; Tsai, 2001). The results of the present

study showed that the relapse group had a more severe Class III pattern than the stable group at T0, which is in accordance with the findings of Baccetti *et al.* (2004) and Ghiz *et al.* (2005). Baccetti *et al.* (2004) indicated that an acute cranial base angle, which would project the mandible forward, greater mandibular length and ramus height of relapse subjects, favoured eventual treatment failure. Ghiz *et al.* (2005) reported that the relapse patients had a more forward position of the mandible relative to the cranial base, a longer mandible and shorter ramus, and an increased gonial angle.

The maxillary incisors in Class III adults have been found to be more proclined (Jacobson *et al.*, 1974; Miyajima *et al.*, 1997), while the maxillary incisors of primary Class III subjects are tipped lingually (Chang *et al.*, 1992; Tsai, 2001). The maxillary incisors in Class III adults may be tipped labially by the tongue while the maxillary incisors in primary Class III subjects are tipped lingually by the retroclined mandibular incisors (Miyajima *et al.*, 1997). In the present study, the maxillary incisors were more labially tipped and the mandibular incisors more lingually tipped in the relapse group than in the stable group, indicating dental compensation in the relapse group.

There was a statistical difference in treatment changes in ANB and UA–SN between the groups. Comparison showed that ANB significantly increased in the relapse group, while UA–SN and is–mo significantly increased, and LA–MP and ii–mo significantly decreased in the stable group. These indicate that correction of the anterior crossbite was mainly due to protrusion of the maxillary incisors and retrusion of the mandibular incisors in the stable group. However, in the relapse group, this was mainly due to the increase of ANB.

Condylar growth during adolescence is a fairly even and approximately 3 mm annually (Björk, 1963), with no pronounced maximum and with a slight decrease to a well-defined prepubertal minimum at 11 years 9 months of age. At a mean age of 14 years 6 months, there is a pubertal maximum, with average growth of about 5 mm (Björk, 1963). Thilander *et al.* (2005) also observed growth acceleration of the mandible between the 13 and 16 year recordings. At T2, the subjects in the present study were only 9–11 years old and pubertal growth had not begun. The magnitude of mandibular growth seemed to be similar in the two groups during T1–T2 but with a difference in the position of the mandible. Ram–SN decreased and gonial angle increased in the relapse group, whereas Ram–SN increased and gonial angle decreased in the stable group. This indicates that the mandible was in a more forward position in the relapse group.

Conclusions

1. Posterior bite raising and 2 × 4 appliance therapy is an effective interceptive treatment of primary anterior crossbites, which are predicted to persist during the transitional dentition using DI.

2. Compared with the stable group, the relapse group showed a more severe Class III craniofacial morphology at T0 and had a more unfavourable growth pattern during T1–T2.
3. Subjects relapsed into reverse overjet mainly due to a shorter maxilla, an increased gonial angle, and a more forward position of the mandible relative to the cranial base.
4. At T2, pubertal growth had not started for most of the treated subjects, so it was not possible to predict the degree of stability of treatment. However, treatment of primary anterior crossbites in this sample fulfilled the expected objectives of interceptive treatment.

References

- al-Sehaibany F, White G 1996 Posterior bite raising effect on the length of the ramus of the mandible in primary anterior crossbite: case report. *Journal of Clinical Pediatric Dentistry* 21: 21–26
- Baccetti T, Franchi L, McNamara J A Jr. 2004 Cephalometric variables predicting the long-term success or failure of rapid maxillary expansion and facemask therapy. *American Journal of Orthodontics and Dentofacial Orthopedics* 126: 16–22
- Björk A 1963 Variations in the growth pattern of the human mandible: longitudinal radiographic study by the implant method. *Journal of Dental Research* 42: Supplement400–411
- Björk A 1972 Timing of interceptive orthodontic measures based on stages of maturation. *Transactions of the European Orthodontic Society* 48: 64–74
- Campbell P M 1983 The dilemma of Class III treatment early or late? *Angle Orthodontist* 53: 175–191
- Chang H P, Kinoshita Z, Kawamoto T 1992 Craniofacial pattern of Class III deciduous dentition. *Angle Orthodontist* 62: 139–144
- Deguchi T, Kanomi R, Ashizawa Y, Rosenstein S W 1999 Very early face mask therapy in Class III children. *Angle Orthodontist* 69: 349–355
- Ghiz M A, Ngan P, Gunel P 2005 Cephalometric variables to predict future success of early orthopedic Class III treatment. *American Journal of Orthodontics and Dentofacial Orthopedics* 127: 301–306
- Graber L W 1977 Chin cup therapy for mandibular prognathism. *American Journal of Orthodontics* 72: 23–41
- Gu Y, Rabie A B M, Hägg U 2000 Treatment effects of simple fixed appliance and reverse headgear in correction of anterior crossbites. *American Journal of Orthodontics and Dentofacial Orthopedics* 117: 691–699
- Hellman M 1932 An introduction to growth of the human face from infancy to adulthood. *International Journal of Orthodontia, Oral Surgery and Radiography* 18: 777–798
- Houston W J B 1983 The analysis of error in orthodontic measurements. *American Journal of Orthodontics* 83: 382–390
- Hua Y M, Shi S Z 2000 The investigation and analysis of deciduous crossbite. *Stomatology* 20: 43–44
- Huang N *et al.* 2005 The malocclusion of primary dentition in the suburb of Chengdu: a cross-section survey. *Hua Xi Kou Qiang Yi Xue Za Zhi* 23: 173–174
- Iizuka T 1953 A study of facial growth in Japanese children using lateral cephalograms. *Journal of Stomatology Society of Japan* 25: 260–272
- Jacobson A, Evans W G, Preston C B, Sadowsky P L 1974 Mandibular prognathism. *American Journal of Orthodontics* 66: 140–171
- Major P W, Glover K 1992 Treatment of anterior crossbite in early mixed dentition. *Journal of the Canadian Dental Association* 58: 574–575
- Miyajima K *et al.* 1995 Posterior bite raising effects on a primary anterior crossbite case. *Journal of Clinical Pediatric Dentistry* 19: 131–134
- Miyajima K, McNamara J A Jr, Sana M, Murata S 1997 An estimation of craniofacial growth in the untreated Class III female with anterior crossbite. *American Journal of Orthodontics and Dentofacial Orthopedics* 112: 425–434
- Nagahara K, Murata S, Nakamura S, Tsuchiya T 2001 Prediction of the permanent dentition in deciduous anterior crossbite. *Angle Orthodontist* 71: 390–395
- Nagahara K, Suzuki T, Nakamura S 1997 Longitudinal changes in the skeletal pattern of deciduous anterior crossbite. *Angle Orthodontist* 67: 439–446
- Onodera K, Niikuni N, Yanagisawa M, Nakajima I 2006 Effects of functional orthodontic appliances in the correction of a primary anterior crossbite—changes in craniofacial morphology and tongue position. *European Journal of Orthodontics* 28: 373–377
- Saadia M, Torres E 2000 Sagittal changes after maxillary protraction with expansion in Class III patients in the primary, mixed, and late mixed dentitions: a longitudinal retrospective study. *American Journal of Orthodontics and Dentofacial Orthopedics* 117: 669–680
- Sakamoto T, Miura F, Iizuka T 1963 Linear analyses on the development changes of dentofacial complex of Japanese by means of roentgenographic cephalometry. *Journal of Stomatology Society of Japan* 30: 169–182
- Takeuchi Y, Genba Y, Suzuki S, Nakamura S 1979 Longitudinal growth study on untreated cases with reversed occlusion. *Journal of Japanese Orthodontic Society* 38: 14–29
- Thilander B 1965 Chin-cap treatment for Angle Class III malocclusion: a longitudinal study. *Transactions of European Orthodontic Society* 41: 311–327
- Thilander B, Persson M, Adolfsson U 2005 Roentgen-cephalometric standards for a Swedish population. A longitudinal study between the ages of 5 and 31 years. *European Journal of Orthodontics* 27: 370–389
- Tollaro I, Baccetti T, Bassarelli V, Franchi L 1994 Class III malocclusion in the deciduous dentition: a morphological and correlation study. *European Journal of Orthodontics* 16: 401–408
- Tsai H H 2001 Components of anterior crossbite in the primary dentition. *ASDC Journal of Dentistry of Children* 68: 27–32
- Tzatzakis V, Gidarakou I K 2008 A new clinical approach for the treatment of anterior crossbites. *World Journal of Orthodontics* 9: 355–365
- Wang Z *et al.* 1999 A follow-up study of anterior deciduous cross-bite. *Hua Xi Kou Qiang Yi Xue Za Zhi* 17: 348–351
- Yao P Y 1984 The investigation and analysis of malocclusion of 3095 children with primary dentition in TianJin. *Zhong Hua Kou Qiang Ke Za Zhi* 19: 117–119